

CASE STUDY CAVALIER KING CHARLES SPANIEL

Clinician: Dr. Diaz

Location:

Species: Canis

Breed: Cavalier King Charles Spaniel

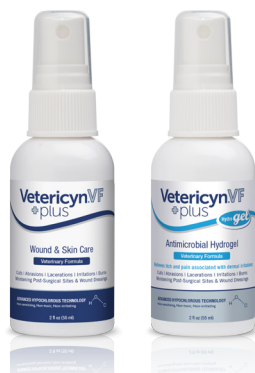Age: 4

Gender: Female

Problem: Large areas of necrotic tissue

Location on patient: On back, top of head, and ear

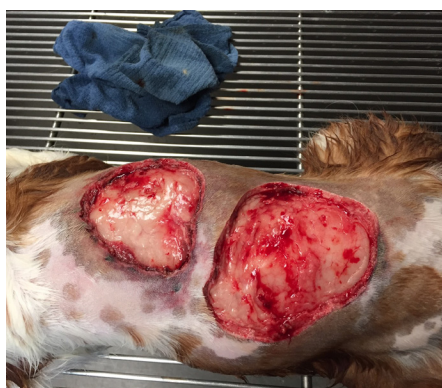Product(s) used: Vetericyn Plus[®] VF Wound and Skin Care Liquid, Vetericyn Plus[®] VF Antimicrobial Hydrogel, and oral antibiotics



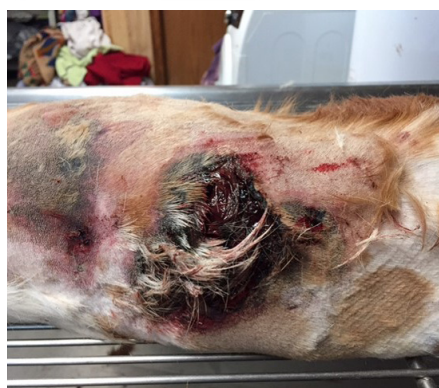Comments & Notes on Treatment: The Cavalier Kind Charles Spaniel presented for treatment four days after being attacked by a male poodle. She had large areas of necrotic tissue over her back and on top of her head and ear.

The affected areas were clipped and flushed with Vetericyn Plus[®] VF Wound and Skin Liquid, and surgical debridement was used to remove necrotic tissue. Once necrotic tissue was removed, the affected areas were flushed again with Vetericyn VF Wound and Skin Care Liquid.

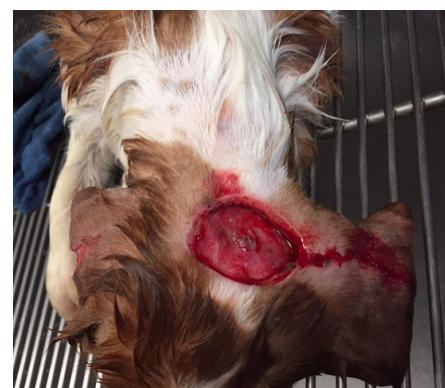As the dog would not tolerate bandaging, the owner was instructed to apply Vetericyn VF Hydrogel 2-3 times daily to all areas. The dog was also given five days of oral antibiotics.



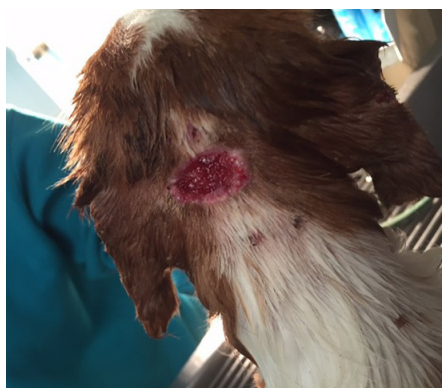1/10/17




1/12/17



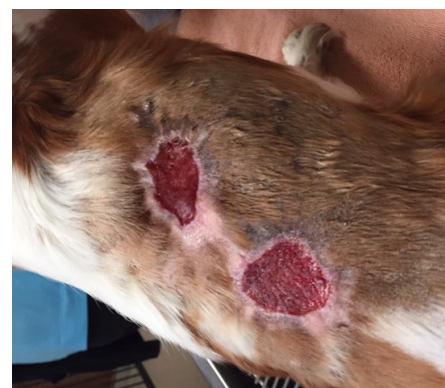1/13/17



1/16/17

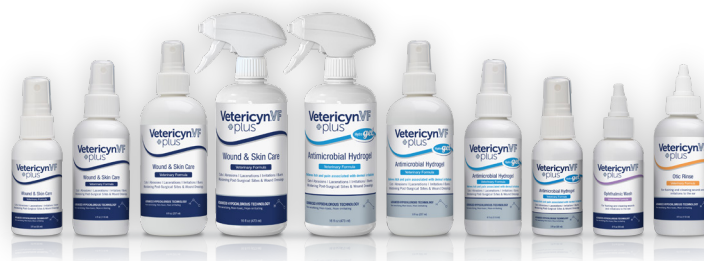

1/27/17



2/1/17

Introducing Vetericyn Plus[®] Veterinary Formula, a new standard in wound care designed to enhance all phases of the wound treatment process.



© 2017 Innovacyn, Inc. All rights reserved. | 912480 v1.0