

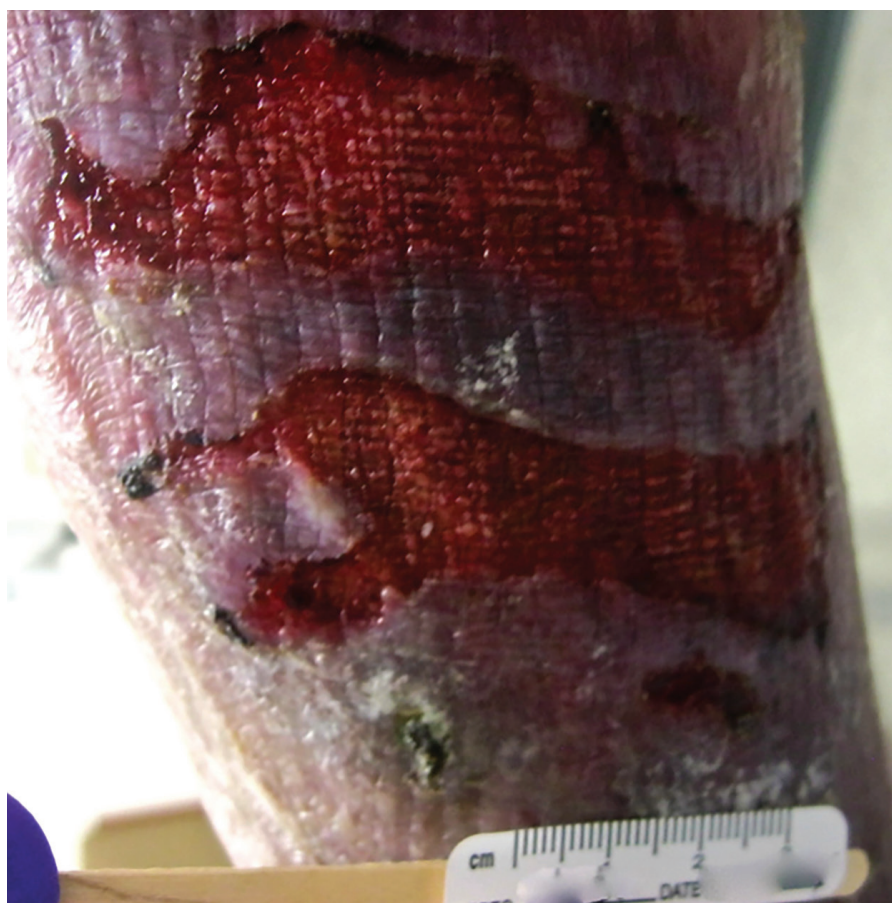


PATIENT HISTORY

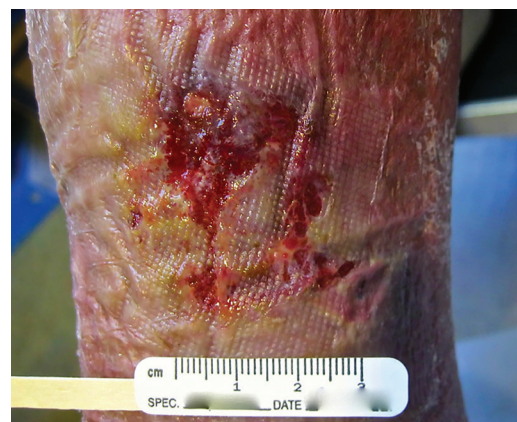The patient was an 84-year-old male with a history of chronic venous insufficiency, coronary artery disease, hypertension, and a cerebral vascular accident. He presented with a chronic venous stasis ulcer of the lower extremity with significant swelling. The patient was

seen twice per week in the office. All devitalized tissue was removed using sharp debridement. Cleansing and irrigation of the wound bed was accomplished at each visit with Puracyn[®] Plus Professional Formula Wound Irrigation Solution. The patient was seen twice a week for

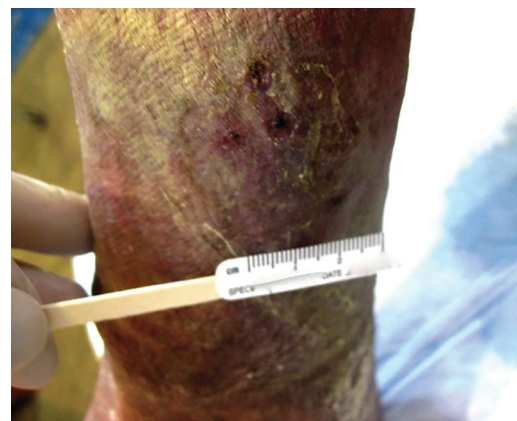
continued wound care. A multilayer compression dressing consisting of Puracyn Plus-moistened sterile gauze, Xeroform, and Coban was utilized during each treatment.



6/3/14 (WEEK 1)



8/24/14 (WEEK 10)



9/7/14 (WEEK 12)